

Abstract

- In the last few years Computer Guided Surgery has become one of the most popular treatment modalities. Some implant companies have developed their own implant guided surgery system.
- In this study we took the advantage of a single implant surgical drilling protocol (NobelGuide; Nobelbiocare Sweden) to compare two different implant systems with slight macrodesign changes and a completely different titanium surface (TiUnite and SBM)
- This is a multicenter clinical study with four clinics and 6 clinicians involved. The group have selected 73 healthy patients to join the study. Selection criteria includes non smokers with good oral health and sufficient healing time after tooth extractions (min 3 months).
- After treatment planning, implants were placed following the same surgical and immediate loading protocol. Panoramic X-rays were taken the day of surgery and at intervals of 6, 12 and 18 months respectively.

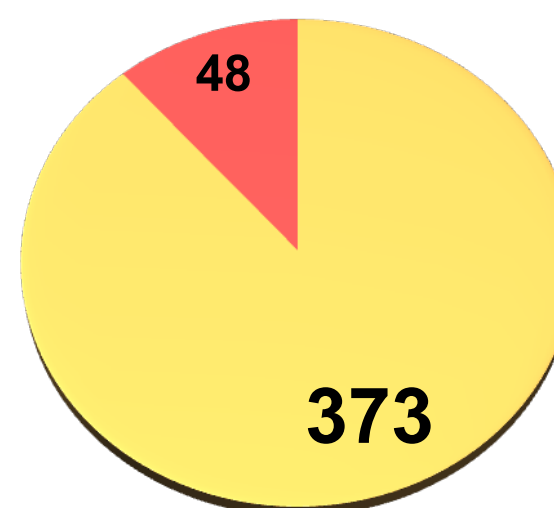
Background and Aim

- In order to test the null hypothesis that two different implants cannot have the same clinical behaviour when placed under the same surgical and loading protocol, random placement of two different implants side by side was done.
- A total of 73 surgeries was performed in four clinical centers with the biggest observation period of 29 months and the lowest being 3 months.

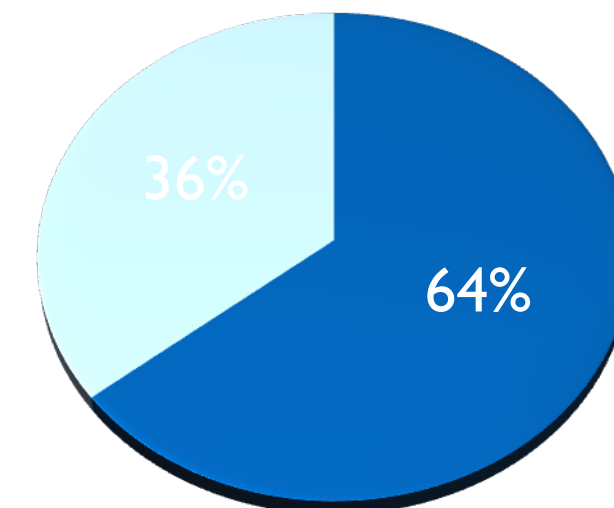
Methods and Materials

- A total of 73 maxillary, partial or fully edentulous healthy patients were selected for the study.
- In each case one or two Nobelbiocare Replace implants (control) were randomly selected for placement in one or two locations. These implants were used to further stabilize the Surgical Guide with a Template abutment.
- The balance of the implants placed were Replant Implant Direct (test).
- All of them were placed following the same Nobelguide surgical protocol and immediately loaded within 24-48h frame time. Panoramic X Rays were taken the day of surgery, and at 6, 12 and 18 months period.
- All the implants were tested to fulfill the success criteria given by Albrektsson including No bone loss, no mobility, no swelling, no pain, good looking and healthy mucosa and no X-ray images surrounding any implant device.

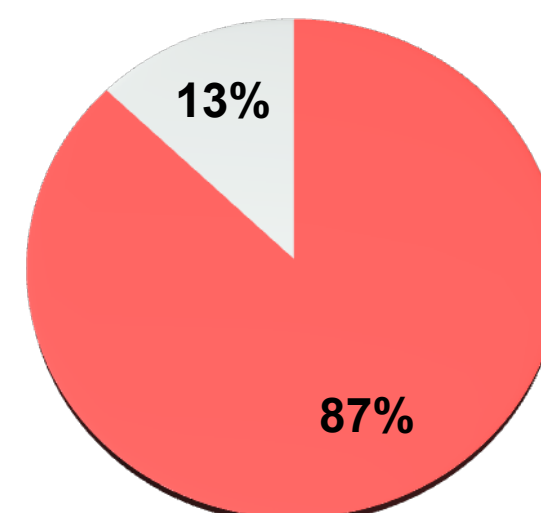
Results



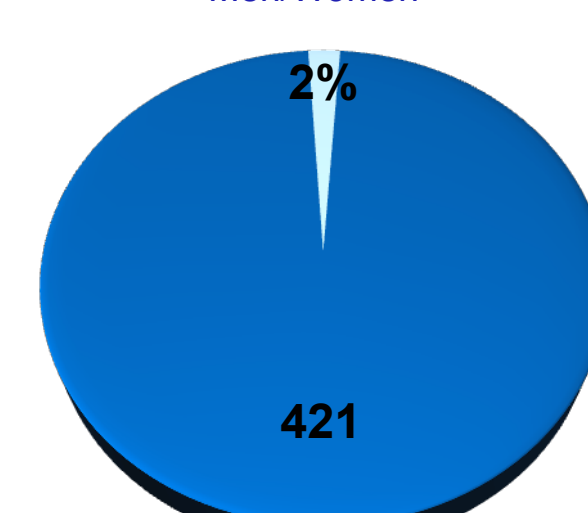
NB / ID



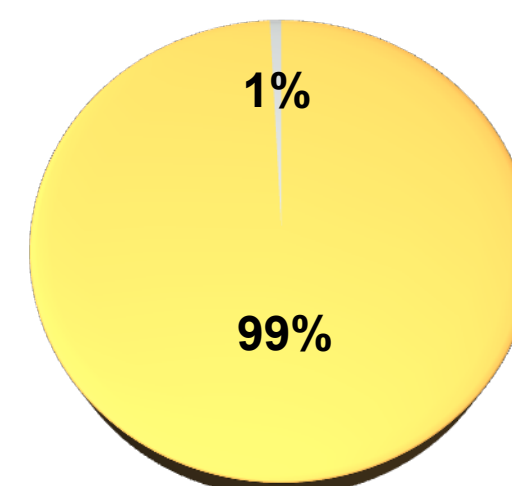
Men/Women



NB % of failures



Total % of failures



ID % of failures

- Of the 73 patients treated, 47 were women and 26 were men and a total of 421 implants were placed.
- The longest observation period was 26 months and the minimum was 3 months.
- A total of 9 implants failed from the 421 implants placed. 6 were Replace (Nobelbiocare) and 3 were RePlant (Implant Direct).
- The percentage failure rate is 2%, with all patients being able to wear their planned final prosthesis.

CONCLUSIONS

- The present experiment failed to prove that two different implants with similar body shape (one with double-lead threads and cervical micro threads and the other not) and two different surface enhancements (TiUnite/ Soluble Blast Media), would have the same clinical outcome
- It can be stated then that both implant systems can successfully be used with the same Stereolithography (SLA) method of surgical guide manufacture
- The percentage of failures is in agreement with previous studies, When separated by product families (Replace vs RePlant) Ti Unite (Oxidized treated) implants failed 13 times more than Ti SBM treated implants.
- The failure differential can be attributed to the surface treatment and how it responds in maxillary bone and/or the slight thread design change over the length of the implant.
- More experiments need to be conducted to further study these results.

References

1. Accuracy of template-based dental implant placement, Int J Oral Maxillofac Implants. 2009 May-Jun;24(3):447-54.
2. Accuracy of computer-aided oral implant surgery: a clinical and radiographic study, Int J Oral Maxillofac Implants 2009 Mar-Apr;24(2):234-42.
3. Computer-guided flapless surgery: immediately loaded implant-prosthetic rehabilitation. Minerva Stomatol. 2009 Mar; 58(3):115-26.
4. Misfit of implant fixed complete denture following computer-guided surgery; IJOMI 2009 Jan-Feb;24(1):124-30